

FootCare Update



Expert care from professionals who care.

Volume III, No. 2; Revised Winter, 2006

Podiatric surgeons have pioneered study and treatment of Morton's Neuroma (pinched nerve).

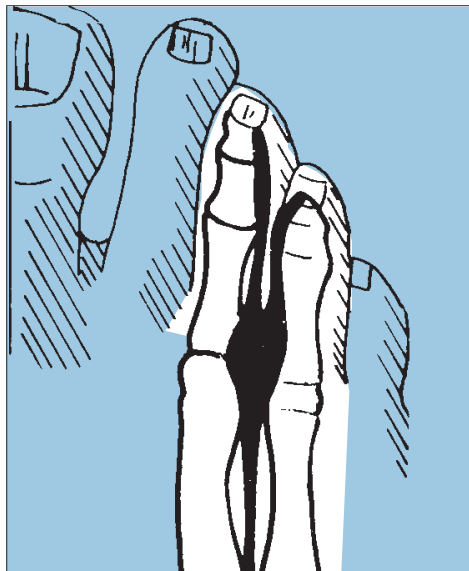
When your patient complains "The ball of my foot feels burning and tingly and there is also some numbness on the bottom of my toes," this is a sure sign of Morton's Neuroma, also referred to as an entrapped or pinched nerve.

Persons of all ages commonly experience neuromas. Their discomfort is not usually present in the morning, but becomes apparent after periods of prolonged standing or walking, according to Kenneth Leavitt, DPM. Pain can often become so severe as to disable the persons from walking, unless they remove their shoe and massage their foot.

What causes a Neuroma?

The cause or causes of Morton's Neuroma are varied and some include biomechanical and /or genetic origins. Apparently the most common explanation is that of tight and/or high heeled shoe gear, which compresses the metatarsal heads together and causes repeated abnormal trauma to the nerves on the bottom of the third and fourth toes. The nerve coating (perineurium) thickens to protect the nerve fibers within, but eventually the thickening overcomes the space for which the nerve was intended, resulting in abnormal central nerve compression.

"The tight shoe explanation does



Most Neuromas occur between the 3rd and 4th metatarsal heads.

seem to correlate with women having the statistical predisposition to incurring Morton's Neuroma," Leavitt said.

Early injections help most patients

If caught in the initial stages, one to three injections of steroid and local anesthetic (attempting to thin out the peroneural fibrosis) in conjunction with an attempt to change shoe gear habits, has been shown to provide success in

the range of 50 per cent, according to Leavitt.

Most often patients present having already experienced the symptoms for six months or more and are unable to undertake the drastic modification of shoe gear which would be necessary to provide any level of successful conservative resolution of the problem. "These patients are most often given at least one attempt at conservative treatment with the local anesthetic/steroid injection," Leavitt said.

Surgical Intervention

The attempt to control mechanics is rarely seen to provide a successful resolution to the problem, especially where the pathology has been present for several months or years.

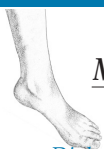The traditional surgical approach of a dorsal incision to remove a section of the thickened nerve has a relatively high success rate in preventing recurrence of the neuroma and eliminating symptoms 85 per cent of the time.

"I can't believe how good my foot feels after my neuroma surgery. It's wonderful."

- Patient

Depending on the particular patient, Dr. Leavitt may use an alternate approach which disrupts less tissue, thereby causing less swelling and enabling quicker recovery.

an alternate approach which disrupts less tissue, thereby causing less swelling and enabling quicker recovery.



Kenneth M. Leavitt, DPM

MEDICINE & RECONSTRUCTIVE SURGERY OF THE FOOT

Doctor of Podiatric Medicine

Fellow, American College of Foot & Ankle Surgeons

Diplomate, American Board of Podiatric Surgery, Certified in Foot Surgery



Neuromas (continued)

ery. “We make a plantar linear incision, placed within skin lines and directly beneath the transverse metatarsal ligament,” Leavitt said. “This location avoids weightbearing areas beneath the third and fourth metatarsal heads.”

Dr. Leavitt is pleased with the results. He considers the benefits of this surgical approach to include:

1) Affords much better visualization; 2) A smaller dead space to prevent the formation of a hematoma; and most importantly 3) Allows for the removal of a greater length of common digital nerve, thus preventing neuroma regrowth and more importantly, a stump adhesion to scar tissue directly beneath the transverse metatarsal ligament.

“With over 100 patients having undergone the surgical procedure through the plantar incision over the past several years, we have seen less than a 1 per cent chance for painful ambulatory scar and have to date seen no symptoms suggestive of stump adhesion or neuroma regrowth,” Leavitt said.

Diagnosing Morton’s Neuromas

A *Morton’s Neuroma* as strictly defined, is the enlargement of a portion of the cutaneous sensory nerves from the plantar aspect from of the bottom of the third and fourth toes. This nerve dystrophy is histopathologically defined as *peri-neural fibrosis*. The peri-neural fibrosis is caused by repeated abnormal trauma to the nerve which results in thickening to protect the nerve fibers. Eventually the thickening overcomes the space for which the nerve was intended, resulting in abnormal central nerve compression.

Who was Morton? - Several individuals named Morton can take credit for describing this condition. T.G. Morton in 1876, after whom the condition was named, inaccurately described the underlying etiology of the problem. But neither D.J. Morton, who accurately described the neuroanatomy, nor Durlacher, an Englishman, who in 1845 understood the condition as having a neurologic etiology, were given name recognition.

Location and Anatomy - The most common location for Morton’s Neuroma is plantar to the transverse metatarsal ligament, which connects the joint capsules of the metatarsals. The sensory nerves from the plantar aspect of the third and fourth toes are common at this point and this common digital nerve is often larger than the common digital nerves to the fourth and fifth toes and the second and third toes. There is a communicating branch off of the common digital branch to the second and third toes which is most likely lending additional size to the common digital branch to the third and fourth toes. This communication with the cutaneous digital branches to the second and third toes is possibly what often gives rise to *referred pain* which the patients sometime sense in the adjacent aspects of the second and third toes.

Second interspace neuromas - Less common, but occurring approximately 10 per cent of the time, is a proper digital neuroma to the second and third toes. Most patients will sense some discomfort within the second, third and fourth toes even in the absence of a second interspace neuroma, due to the communicating branch. Second interspace neuromas do occur, but usually are diagnosed by exclusion, i.e. following excision of a third interspace neuroma or in the presence of overriding clinical evidence that the patient’s pain is confined to the plantar aspect of the second and third toes.



Kenneth Martin Leavitt, D.P.M.

MEDICINE & RECONSTRUCTIVE SURGERY OF THE FOOT

New England Baptist Hospital, Suite 390 • 125 Parker Hill Ave. • Boston, MA 02120

TEL: 617-277-3800 • FAX: 617-277-3808

E-MAIL: kenleavitt@earthlink.net • www.bostonfootandankle.com